



RESENTING CLINICAL SIGNS

History: Grade 2/6 left-sided murmur. Asymptomatic.

DATE

8/4/22

ECHOCARDIOGRAPHIC FINDINGS

2D, M-mode, and Doppler study.

PERFORMED BY:

Diane McFadden

INTERPRETED BY

Keith Blass, DVM,
MS, DACVIM
(Cardiology)

Left atrial size is normal. The mitral valve leaflets are thickened and exhibit systolic prolapse. A mild to moderate jet of mitral regurgitation is present. Left ventricular dimensions are normal. Left ventricular systolic function is hyperdynamic. The aorta and aortic valve appear normal, though mild aortic insufficiency is present. Right atrial and right ventricular dimensions are normal. The tricuspid valve appears normal, though trace tricuspid regurgitation is present. The pulmonary artery and pulmonic valve are normal. No shunting lesions are visualized. No pericardial effusion or cardiac masses are seen.

LA - 24.8 mm
LVIDd - 26.2 mm
LVIDs - 12.1 mm
FS - 53.8%
RA - 15.4 mm
LVOT - 1.48 m/s
RVOT - 1.06 m/s

PATIENT

Maggie Graessle

SPECIES

Canine

BREED

Maltese Mix

ASSESSMENT/RECOMMENDATIONS

Degenerative mitral valve disease

This examination demonstrates mild to moderate regurgitation of blood across Maggie's mitral valve resulting from degenerative valve disease. The hemodynamic effects of the regurgitation appear to be mild, as Maggie does not have secondary dilation of either of her left heart chambers, and her left ventricular systolic function is well-preserved. As such, Maggie's mitral valve disease appears to be well-compensated, and her current risk for the development of clinical signs secondary to it, such as coughing, exercise intolerance, syncope, and labored breathing, appears to be low.

SEX

No therapy is recommended at this stage of disease.

FS

A recheck echocardiogram is recommended in 6 months to monitor for disease progression.

AGE

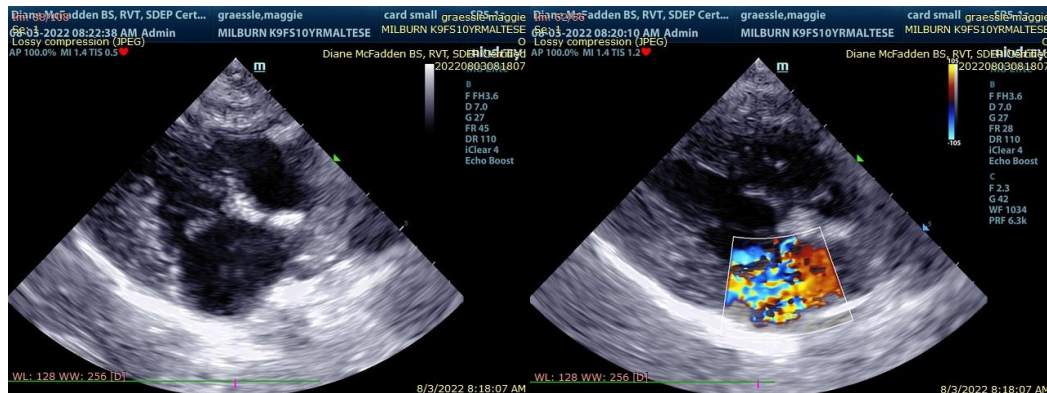
10 y

WEIGHT

14 lb

HOSPITAL NAME

Milburn VH



REFERRING VET

Dr. Turowsky

The information and recommendations provided are based on the images presented by the



referring veterinarian. No evaluation can be communicated regarding pathology that was not visible in the image/video clips provided.

DATE

8/4/22

Thank you for this referral. If the clinical or image interpretation does not parallel your findings or if I can be of any further assistance please contact me.

PERFORMED BY: Keith Blass, DVM, MS, DACVIM (Cardiology)

KeithBlass@gmail.com
631-804-5754

Diane McFadden

INTERPRETED BY

Keith Blass, DVM,
MS, DACVIM
(Cardiology)

PATIENT

Maggie Graessle

SPECIES

Canine

BREED

Maltese Mix

SEX

FS

AGE

10 y

WEIGHT

14 lb

HOSPITAL NAME

Milburn VH

REFERRING VET

Dr. Turowsky